This article was downloaded by: [Aristotle University of Thessaloniki]
On: 20 December 2014, At: 01:10
Publisher: Routledge
Informa Ltd Registered in England and Wales Registered Number: 1072954 Registered office: Mortimer House, 37-41 Mortimer Street, London W1T 3JH, UK



CrossMark
Click for updates

Aphasiology
Publication details, including instructions for authors and subscription information:
http://www.tandfonline.com/loi/paph20

A brief assessment of object semantics in primary progressive aphasia

Bonnie L. Breining[a], Trisha Lala[b], Macarena Martínez Cuitiño[cde], Facundo Manes[cdfgh], Eleni Peristeri[i], Kyrana Tsapkini[j], Andreia V. Faria[k] & Argye E. Hillis[ajl]

[a] Department of Cognitive Science, Johns Hopkins University, Baltimore, MD, USA

[b] Department of Neuroscience, Johns Hopkins University, Baltimore, MD, USA

[c] Institute of Cognitive Neurology (INECO), Buenos Aires, Argentina

[d] Institute of Neuroscience, Favaloro University, Buenos Aires, Argentina

[e] Institute of Linguistics, University of Buenos Aires, Buenos Aires, Argentina

[f] UDP-INECO Foundation Core on Neuroscience (UIFCoN), Diego Portales University, Santiago, Chile

[g] Australian Research Council (ACR) Centre of Excellence in Cognition and its Disorders, Sydney, Australia

[h] National Scientific and Technical Research Council (CONICET), Buenos Aires, Argentina

[i] Department of English Studies, Aristotle University of Thessaloniki, Thessaloniki, Greece

[j] Department of Neurology, Johns Hopkins University, Baltimore, MD, USA

[k] Department of Radiology, Johns Hopkins University, Baltimore, MD, USA

[l] Department of Physical Medicine & Rehabilitation, Johns Hopkins University, Baltimore, MD, USA

Published online: 31 Oct 2014.

To cite this article: Bonnie L. Breining, Trisha Lala, Macarena Martínez Cuitiño, Facundo Manes, Eleni Peristeri, Kyrana Tsapkini, Andreia V. Faria & Argye E. Hillis (2014): A brief assessment of object semantics in primary progressive aphasia, Aphasiology, DOI: 10.1080/02687038.2014.973360

To link to this article: http://dx.doi.org/10.1080/02687038.2014.973360

PLEASE SCROLL DOWN FOR ARTICLE

Taylor & Francis makes every effort to ensure the accuracy of all the information (the "Content") contained in the publications on our platform. However, Taylor & Francis, our agents, and our licensors make no representations or warranties whatsoever as to the accuracy, completeness, or suitability for any purpose of the Content. Any opinions and views expressed in this publication are the opinions and views of the authors, and are not the views of or endorsed by Taylor & Francis. The accuracy of the Content should not be relied upon and should be independently verified with primary sources of information. Taylor and Francis shall not be liable for any losses, actions, claims, proceedings, demands, costs, expenses, damages, and other liabilities whatsoever or howsoever caused arising directly or indirectly in connection with, in relation to or arising out of the use of the Content.

This article may be used for research, teaching, and private study purposes. Any substantial or systematic reproduction, redistribution, reselling, loan, sub-licensing, systematic supply, or distribution in any form to anyone is expressly forbidden. Terms & Conditions of access and use can be found at http://www.tandfonline.com/page/terms-and-conditions

Downloaded by [Aristotle University of Thessaloniki] at 01:11 20 December 2014

Aphasiology, 2014
http://dx.doi.org/10.1080/02687038.2014.973360

Downloaded by [Aristotle University of Thessaloniki] at 01:11 20 December 2014

A brief assessment of object semantics in primary progressive aphasia

Bonnie L. Breining[a]*, Trisha Lala[b], Macarena Martínez Cuitiño[c,d,e], Facundo Manes[c,d,f,g,h], Eleni Peristeri[i], Kyrana Tsapkini[j], Andreia V. Faria[k] and Argye E. Hillis[a,j,l]

[a]*Department of Cognitive Science, Johns Hopkins University, Baltimore, MD, USA;* [b]*Department of Neuroscience, Johns Hopkins University, Baltimore, MD, USA;* [c]*Institute of Cognitive Neurology (INECO), Buenos Aires, Argentina;* [d]*Institute of Neuroscience, Favaloro University, Buenos Aires, Argentina;* [e]*Institute of Linguistics, University of Buenos Aires, Buenos Aires, Argentina;* [f]*UDP-INECO Foundation Core on Neuroscience (UIFCoN), Diego Portales University, Santiago, Chile;* [g]*Australian Research Council (ACR) Centre of Excellence in Cognition and its Disorders, Sydney, Australia;* [h]*National Scientific and Technical Research Council (CONICET), Buenos Aires, Argentina;* [i]*Department of English Studies, Aristotle University of Thessaloniki, Thessaloniki, Greece;* [j]*Department of Neurology, Johns Hopkins University, Baltimore, MD, USA;* [k]*Department of Radiology, Johns Hopkins University, Baltimore, MD, USA;* [l]*Department of Physical Medicine & Rehabilitation, Johns Hopkins University, Baltimore, MD, USA*

(*Received 3 June 2014; accepted 30 September 2014*)

Background: A cross-culturally valid nonverbal assessment of semantic knowledge is needed. Accurately identifying impairment of object semantics is important for diagnosis of several disorders, including distinguishing semantic variant primary progressive aphasia (svPPA), a neurodegenerative condition characterised by progressive impairment in word comprehension, from logopenic and nonfluent agrammatic variants, which are not associated with impaired object semantics. However, current assessments require culturally specific knowledge.
Aims: We developed a cross-culturally valid short form of the Pyramids and Palm Trees Test to assess object semantic memory. We investigated its clinical utility in differentiating the semantic variant of primary progressive aphasia, from the logopenic and nonfluent agrammatic variants. Areas of atrophy associated with poor performance were identified.
Methods & Procedures: Fourteen items that rely on knowledge of objects' defining features were selected from the original 52-item version. The full and short forms were administered to healthy individuals in the US ($N = 18$), Argentina ($N = 20$), and Greece ($N = 12$) and performance was compared. Seventy-eight individuals with primary progressive aphasia in the US completed the short form. Behavioural performance of the svPPA group ($N = 24$) was compared to other variants. Atlas-based analysis identified regions where atrophy correlated with poor performance in 39 individuals with primary progressive aphasia who had high-resolution magnetic resonance imaging (MRI) scans.
Outcomes & Results: Control performance was classified as normal on the short form significantly more often than on the full version. Across groups with primary progressive aphasia, the group with semantic variant performed significantly worse than the groups with logopenic or nonfluent agrammatic variants. Volume in left anterior and inferior temporal cortex correlated with performance.
Conclusions: The short-form Pyramids and Palm Trees Test is a clinically relevant, cross-culturally valid assessment of nonverbal object semantics. It can be used to identify semantic impairments, with poor performance associated with atrophy of the temporal lobes.

*Corresponding author. Email: breining@jhu.edu

© 2014 Taylor & Francis

Keywords: primary progressive aphasia (PPA); object semantics; nonverbal assessment of semantics; atlas-based analysis; cross-culturally valid assessment

Downloaded by [Aristotle University of Thessaloniki] at 01:11 20 December 2014

Semantic memory refers to conceptual knowledge shared by all speakers of a language, such as features that define an object and distinguish it from other objects (e.g., Patterson, Nestor, & Rogers, 2007; Tulving, 1972; Warrington, 1975). Accurate assessment is clinically important. For example, performance on semantic memory tasks is used to distinguish semantic variant primary progressive aphasia (svPPA) from logopenic variant primary progressive aphasia (lvPPA) and nonfluent agrammatic variant primary progressive aphasia (nfvPPA) (Gorno-Tempini et al., 2011). Although all three variants are characterised by disproportionate language decline in the face of relatively intact cognitive function in other domains, only svPPA is characterised by impaired object semantics while nfvPPA is characterised by agrammatism in language production and/or apraxia of speech and lvPPA is characterised by impaired phonological short-term memory (e.g., Gorno-Tempini et al., 2004; Grossman et al., 1996; Hillis et al., 2006; Hillis, Oh, & Ken, 2004; Hillis, Tuffiash, & Caramazza, 2002; Hodges, Patterson, Oxbury, & Funnell, 1992; Josephs et al., 2006; Mesulam, 1982, 2007; Nestor et al., 2003; Thompson, Lukic, King, Mesulam, & Weintraub, 2012).

The Pyramids and Palm Trees Test (PPT) is one widely used clinical assessment of semantic memory (Howard & Patterson, 1992). Participants match a picture of a reference object (e.g., GLASSES) to the more associated of two objects depicted below it (e.g., target: EYE or distractor: EAR). Unfortunately, many of this assessment's 52 items require culturally specific knowledge (e.g., WINDMILL: TULIP vs. DAFFODIL). Moreover, individuals with substantial deficits are often unable to complete the entire task in the time available during a typical clinic visit.

To efficiently evaluate semantic memory for objects and identify clinically significant impairments, we designed a 14-item version of the PPT that eliminated many culturally specific items. We evaluate the assessment's cross-cultural validity by administering it to healthy individuals in Argentina, Greece, and the US. We expect that these healthy individuals should perform at ceiling because they all share the conceptual information tapped by the test. Furthermore, if the short form accurately assesses object semantic memory, performance should be more impaired, at a group level, in individuals with svPPA, which is associated with impairments of semantic memory, compared to other variants of PPA, in which semantic memory is spared until late in the course. The test might not identify all individuals with svPPA, particularly early in the condition, as the diagnosis requires word comprehension deficits, but not semantic memory deficits. Additionally, if the short form evaluates semantic memory, poor performance should correlate with atrophy in left or bilateral anterior and inferior temporal cortex, areas disproportionately atrophied in svPPA that are also associated with semantic memory in other populations (e.g., Binder, Desai, Graves, & Conant, 2009; Binder et al., 2011; Bright, Moss, & Tyler, 2004; Caramazza & Mahon, 2003; Devlin et al., 2000; Galton et al., 2001; Gorno-Tempini et al., 2011; Marinkovic et al., 2003; Mummery et al., 2000; Newhart, Ken, Kleinman, Heidler-Gary, & Hillis, 2007; Noppeney et al., 2007; Price, Devlin, Moore, Morton, & Laird, 2005; Rogers et al., 2006; Schwartz et al., 2009; Tyler & Moss, 2001; Visser, Jefferies, & Lambon Ralph, 2010). To evaluate these hypotheses, the short form was also administered to individuals with PPA in the US. A short assessment that taps knowledge shared by healthy individuals in multiple cultures, that identifies clinically significant impairments in semantic memory, and that is associated

with damage to previously demonstrated neural correlates of semantic memory is one that will be widely useful.

Methods

Participants

We enrolled a series of 76 participants with PPA from the senior author's neurology clinic: 24 with svPPA, 23 with lvPPA, and 27 with nfvPPA as classified based on published guidelines (Gorno-Tempini et al., 2011) as well as 2 unclassifiable in early stages of PPA who presented as anomic and dysgraphic without defining features of any variant including no impairment on other measures of semantic memory. We included only PPA participants who were able to successfully complete the experimental task. They all appeared to understand the task instructions; they consistently selected one or the other picture at the bottom of the page (see later for a description of the task). The PPA participants were aged 48–84 years and had 12–20 years of education. A subset of 39 PPA participants—11 with svPPA, 14 with lvPPA, 12 with nfvPPA, and 2 with unclassifiable PPA—had high resolution magnetic resonance imaging (MRI) within 6 months of behavioural assessment and were included in the imaging study.

The 52-item PPT was also administered to 50 neurologically intact control participants aged 43–80 years in Argentina (N = 20), Greece (N = 12), and US (N = 18) with 7–23 years of education. Although control participants were selected to be in the same age group as the PPA participants, they were on average younger than the participants with PPA, mean age of control participants = 57.2 years, standard deviation = 8.41; mean age of PPA participants = 68 years, standard deviation = 8.84. Participants gave informed written consent in accordance with local ethics policies. The study was approved by the Johns Hopkins Institutional Review Board.

Stimuli

To create the Short Form of the Pyramids and Palm Trees Test, we selected 14 items (listed in Table 1) from the 52 used in the full version of the PPT (Howard & Patterson,

Table 1. Items included in the short-form Pyramids and Palm Trees Test.

Reference item	Target	Distractor
Ink	Pen	Pencil
Baby	Crib	Bed
Drill	Screw	Nail
Dog house	Dog	Cat
Cheese	Mouse	Rabbit
Tent	Camp fire	Radiator
Web	Spider	Bee
Matches	Candle	Light bulb
Tree orchard	Apple	Onion
Mice	Cat	Dog
Pillow	Bed	Chair
Glasses	Eye	Ear
Wood	Saw	Hammer
Curtain	Window	Door

Downloaded by [Aristotle University of Thessaloniki] at 01:11 20 December 2014

1992). Each item consists of three black and white line drawings: a reference object presented above a target association object and a semantic coordinate distractor object. Only the picture version of the task, not a word version or combined picture and word version, was administered in this study. In selecting items for the short form, our goal was to remove items that rely more on cultural knowledge than on knowledge of an object's defining features. In order to do this, we gave the complete test to 10 healthy controls in the US and asked them if they could select which picture was more related to the reference item on the basis of the meaning of the item alone. If they thought there was no correct answer, they could respond neither. We eliminated items that two or more people scored as neither. We also eliminated items with ambiguous or difficult to interpret pictures. For example, the "mayor" picture is a man with a medal around his neck, a depiction that is unfamiliar to people in the US, where mayors do not typically wear such regalia. Our first design of the short form included 15 items, a number that could efficiently be administered in clinical settings, even to individuals with substantial semantic deficits. However, one item was later removed (FORK: SPOON vs. LADLE) because it was a practice item in some published versions of the Pyramids and Palm Trees Test and because in Greece, one of the locations where we investigated cross-cultural validity, the same root word is used for spoon and ladle. Removing this item left us with a 14-item short form.

Analysis of behavioural measures

Primary progressive aphasia

A Kruskal–Wallis one-way analysis of variance was used to evaluate differences in svPPA, lvPPA, and nfvPPA groups' performance on the short-form PPT. Planned comparisons were conducted to compare svPPA to the other PPA participant groups. The few individuals with unclassifiable PPA ($N = 2$) were not included in these analyses: their data contribute only to the imaging analysis.

Controls

Performance data for the 14 items of the short form were extracted from the administration of the full form. Control performance on the full form was compared to performance on the short form. First, Receiver Operating Curve (ROC) statistics were used to determine the most accurate cut-off that distinguished svPPA participants from controls. Based on this, a chi-square test was used to compare the number of controls scoring below the normal range on the short form to the number of controls scoring below the published normal range on the full-form PPT.

Imaging analysis

Using a 3T whole-body MRI scanner, we acquired MPRAGE T1-WIs (TR/TE = 8.4/3.9 ms) with axial orientation and image matrix of 256 × 256 mm. All scans were conducted within 6 months of completing the short-form PPT (mean interval = 0.58 months with behavioural assessment preceding scanning, standard deviation = 2.5 months).

An atlas-based analysis was used to determine the volume of each anatomical region. In this analysis, multiple regions of interest are automatically defined in each individual

Downloaded by [Aristotle University of Thessaloniki] at 01:11 20 December 2014

brain by applying the anatomical parcellation previously defined in an atlas template (Faria et al., 2010; Oishi et al., 2008). The mapping between the template and each individual's brain was performed with DiffeoMap (Li, X.; Jiang, H.; and Mori, S.; Johns Hopkins University, www.MriStudio.org) and consisted of an initial linear transformation followed by the large deformation diffeomorphic metric mapping (Ceritoglu et al., 2009; Faria et al., 2011, 2010; Mori et al., 2008; Oishi et al., 2009, 2008). Previous studies have demonstrated that the accuracy of this automated segmentation rivals the manual delineation of structures, the gold standard of parcellation (Faria et al., 2011, 2010; Mori et al., 2008), even in the presence of severe atrophy (Oishi et al., 2009).

In the present study, we focused on cortical parcels (n = 76). For the most part, the parcellation follows classical anatomical boundaries (i.e., sulci and gyri). The temporal lobes, for example, which are of special interest to us, are divided into superior, middle, and inferior gyri. The temporal poles (superior and inferior) are defined by a vertical plane through the anterior commissure, based on the anterior ending of the superior temporal sulcus. The inferior and superior temporal poles were separated in the atlas template because they have different connectivity with other regions (Insausti et al., 1998; Kondo, Saleem, & Price, 2003, 2005; Stefanacci, Suzuki, & Amaral, 1996). The portions of the superior, middle, and inferior temporal gyri lying posterior to the pole are further subdivided by a vertical plane crossing the postcentral gyrus. This gross anatomical boundary is used as opposed to more subtle sulci that demarcate Brodmann's areas because they can be more reliably identified in the presence of atrophy. The resulting subdivisions are here called medium superior, medium inferior, and anterior middle temporal gyri.

For each area, the volume measurement was transformed to a z-score based on a population of 39 healthy individuals in the same age range in order to account for age effects since volume declines with age even in healthy individuals. A linearly fitted model of age in logarithmic scale versus volume of each region was calculated, and z-scores were derived using the standard deviations of the predicted values of this model. Linear (Pearson) correlations between scores on the short-form PPT and the z-scores of volumes were calculated. The significance level was set at p-value < 0.05 after using the Bonferroni correction for multiple comparisons.

Results

Behavioural analysis

Primary progressive aphasia

Performance for each of the 76 individuals with PPA is shown in Table 2.

We used nonparametric statistical tests due to violations of homogeneity of variance between the PPA groups, as revealed by Levene's test, $F(2,71) = 11.042$, $p < .001$. A one-way Kruskal–Wallis test revealed group differences, $\chi^2(2, N = 74) = 26.335$, $p < .001$. Pairwise comparisons using the Dunn test with Bonferroni correction revealed that individuals with svPPA, mean rank = 21.69, were significantly less accurate than individuals with lvPPA, mean rank = 40.52, $z = 18.834$, $p = .002$, or nfvPPA, mean rank = 48.98; $z = 27.294$, $p < .001$, while individuals with lvPPA and nfvPPA performed similarly, $z = -8.460$, $p = .365$.

Controls

Performance for each of the 50 control participants is shown in Table 3.

Downloaded by [Aristotle University of Thessaloniki] at 01:11 20 December 2014

Downloaded by [Aristotle University of Thessaloniki] at 01:11 20 December 2014

Table 2. Performance of individuals with primary progressive aphasia (n = 78) on the short-form Pyramids and Palm Trees Test, as well as demographic information and performance on measures of noun naming (picture confrontation naming) and comprehension (word–picture matching).

Participant	PPA variant	Included in imaging	Age	Education	Gender	Disease duration (months)	Short-form PPT score (max 14)	Noun naming (% correct)*	Noun comprehension (% correct)§
L1	Logopenic	Yes	79	18	Female	24	5	20.00	
L2	Logopenic	Yes	68	13.5	Male	66	12	53.33	83.33
L3	Logopenic	Yes	72	18	Male	67	13	33.33	73.33
L4	Logopenic	Yes	71	12	Female	48	13	93.33	76.47
L5	Logopenic	Yes	73	16	Female	109	14	13.33	66.67
L6	Logopenic	Yes	76	18	Female	31	14	81.25	83.33
L7	Logopenic	Yes	66	18	Female	67	14	76.67	93.33
L8	Logopenic	Yes	70	18	Female	43	14	53.33	94.12
L9	Logopenic	Yes	55	18	Male	12	14	83.33	96.67
L10	Logopenic	Yes	76	12	Male	19	14	56.67	100.00
L11	Logopenic	Yes	69	16	Female	51	14	93.33	100.00
L12	Logopenic	Yes	71	16	Male	33	14	100.00	100.00
L13	Logopenic	Yes	64	18	Female	24	14	100.00	
L14	Logopenic	Yes	72	18	Male	25	14	100.00	
L15	Logopenic	No	77	12	Female	25	9	81.25	66.67
L16	Logopenic	No	65	12	Female	86	12	0.00	90.00
L17	Logopenic	No	68	16	Female	96	12	20.00	
L18	Logopenic	No	79	15	Male	77	13	86.67	88.24
L19	Logopenic	No	69	16	Female	59	13	86.67	
L20	Logopenic	No	68	18	Female	51	14	86.67	76.47
L21	Logopenic	No	73	20	Male	12	14	95.00	96.67
L22	Logopenic	No	74	18	Female	58	14	50.00	100.00
L23	Logopenic	No	75		Male	19	14	66.67	100.00
N1	Nonfluent	Yes	79	14	Female	36	9	23.33	16.67
N2	Nonfluent	Yes	52	16	Female	46	14	53.33	70.00
N3	Nonfluent	Yes	84	14	Female	16	14	93.33	94.12
N4	Nonfluent	Yes	48	12	Male	83	14	60.00	96.67
N5	Nonfluent	Yes	75	16	Male	20	14	80.00	100.00

(*continued*)

Downloaded by [Aristotle University of Thessaloniki] at 01:11 20 December 2014

Table 2. (*Continued*).

Participant	PPA variant	Included in imaging	Age	Education	Gender	Disease duration (months)	Short-form PPT score (max 14)	Noun naming (% correct)*	Noun comprehension (% correct)§
N6	Nonfluent	Yes	69	16	Female	32	14	93.33	100.00
N7	Nonfluent	Yes	65	16	Female	49	14	100.00	100.00
N8	Nonfluent	Yes	75	18	Female	103	14	100.00	100.00
N9	Nonfluent	Yes	62	16	Male	12	14	100.00	100.00
N10	Nonfluent	Yes	73	14	Male	23	14	100.00	100.00
N11	Nonfluent	Yes	71	14	Male	49	14	60.00	
N12	Nonfluent	Yes	72	14	Female	30	14	100.00	
N13	Nonfluent	No	67	18	Female	52	10	93.33	52.94
N14	Nonfluent	No	54	16	Female	14	13		
N15	Nonfluent	No	65	18	Female	92	14	40.00	70.00
N16	Nonfluent	No	68	19	Male	20	14	33.33	100.00
N17	Nonfluent	No	84	12	Male	12	14	66.67	100.00
N18	Nonfluent	No	81	16	Male	36	14	76.67	100.00
N19	Nonfluent	No	59	16	Male	37	14	90.00	100.00
N20	Nonfluent	No	50	18	Male	26	14	90.00	100.00
N21	Nonfluent	No	72	18	Female	25	14	93.33	100.00
N22	Nonfluent	No	83	16	Female	86	14	93.33	100.00
N23	Nonfluent	No	59	14	Male	13	14	100.00	100.00
N24	Nonfluent	No	52		Male	13	14	100.00	96.67
N25	Nonfluent	No	84	12	Male	61	14	60.00	
N26	Nonfluent	No	62	16	Male	13	14	93.33	
N27	Nonfluent	No	68	12	Female	46	14	96.67	
S1	Semantic	Yes	58	18	Female	10	7	13.33	64.71
S2	Semantic	Yes	60	16	Female	30	7	60.00	
S3	Semantic	Yes	63	16	Male	38	9	46.67	
S4	Semantic	Yes	74	16	Female	124	10	26.67	
S5	Semantic	Yes	71	18	Male	43	11	30.00	0.00
S6	Semantic	Yes	62	19	Male	66	11	13.33	23.53
S7	Semantic	Yes	59	13	Male	46	11	63.33	95.00

(*continued*)

Downloaded by [Aristotle University of Thessaloniki] at 01:11 20 December 2014

Table 2. (*Continued*).

Participant	PPA variant	Included in imaging	Age	Education	Gender	Disease duration (months)	Short-form PPT score (max 14)	Noun naming (% correct)*	Noun comprehension (% correct)§
S8	Semantic	Yes	67	14	Female	85	13	30.00	80.00
S9	Semantic	Yes	76	12	Female	24	14	30.00	86.67
S10	Semantic	Yes	68	18	Female	13	14	33.33	88.24
S11	Semantic	Yes	61	16	Male	37	14	20.00	93.33
S12	Semantic	No	63	12	Female	42	1	13.33	0.00
S13	Semantic	No	70	20	Male	16	2	100.00	11.76
S14	Semantic	No	61	20	Male	115	3	6.67	0.00
S15	Semantic	No	74	16	Female	25	8	0.00	0.00
S16	Semantic	No	61	18	Male	12	9	66.67	66.67
S17	Semantic	No	72	12	Female	42	10	60.00	47.06
S18	Semantic	No	53	13	Female	37	11	30.00	100.00
S19	Semantic	No	74	16	Male	18	12	33.33	47.06
S20	Semantic	No	65	13	Male	25	12	13.33	50.00
S21	Semantic	No	68	14	Female	17	12	93.33	
S22	Semantic	No	61	18	Female	60	13	50.00	93.33
S23	Semantic	No	74	18	Male	30	14	30.00	93.33
S24	Semantic	No	61	13	Female	24	14	60.00	100.00
U1	Unclassifiable	Yes	75	18	Male	25	14	96.67	100.00

(*continued*)

Downloaded by [Aristotle University of Thessaloniki] at 01:11 20 December 2014

Table 2. (*Continued*).

Participant	PPA variant	Included in imaging	Age	Education	Gender	Disease duration (months)	Short-form PPT score (max 14)	Noun naming (% correct)*	Noun comprehension (% correct)§
U2	Unclassifiable	Yes	59	12	Female	22	14	100.00	100.00
	Logopenic	Mean	70.9	16.2		47.9	13.0	66.558	88.072
	N = 23	SD	5.44	2.45		27.48	2.10	30.9325	11.8192
		Range	55–79	12–20		12–109	5–14	0–100	66.67–100
	Nonfluent	Mean	67.9	15.4		38.7	13.6	80.385	90.336
	N = 27	SD	10.98	2.08		26.41	1.21	23.1771	21.2775
		Range	48–84	12–19		12–103	9–14	23.33–100	16.67–100
	Semantic	Mean	65.7	15.8		40.8	10.1	38.472	57.034
	N = 24	SD	6.32	2.60		30.22	3.80	26.1356	38.4222
		Range	53–76	12–20		10–124	1–14	0–100	0–100
	Unclassifiable	Mean	67.0	15.0		23.5	14.0	98.333	100.000
	N = 2	SD	11.31	4.24		2.12	0.00	2.3570	0.0000
		Range	59–75	12–18		22–25	14	96.67–100	100
	Overall	Mean	68.1	15.8		41.8	12.3	63.211	79.066
	N = 76	SD	8.29	2.39		27.71	2.94	31.8945	30.0528
		Range	48–84	12–20		10–124	1–14	0–100	0–100

Notes: Blank cells indicate that a measure was not available for that individual.
*The noun naming task was a picture naming task (n = 30) described in Hillis et al. (2006) or a picture naming task (n = 16) from the frontotemporal temporal lobar degeneration (FTLD) module of the National Alzheimer's Coordinating Center (NACC) Uniform Data Set, also described in Thompson et al. (2012).
§The noun comprehension task was a word–picture verification task with semantic foils described in Hillis et al. (2006) or a word–picture matching task with semantic foils from the FTLD module of the NACC Uniform Data Set, also described in Rogalsky, Love, Driscoll, Anderson, and Hickok (2011).

Downloaded by [Aristotle University of Thessaloniki] at 01:11 20 December 2014

Table 3. Control performance (n = 50) on the short-form Pyramids and Palm Trees Test.

	Argentina			Greece			US		
	Age (years)	52-item PPT score	14-item PPT score	Age (years)	52-item PPT score	14-item PPT score	Age (years)	52-item PPT score	14-item PPT score
	67	49	14	53	45	12	70	50	14
	74	50	14	50	47	14	68	51	14
	70	52	14	50	47	14	46	47	14
	54	52	14	50	49	14	72	49	14
	52	52	14	51	44	14	52	50	14
	51	52	14	50	48	14	80	49	14
	53	52	14	52	46	14	64	52	14
	60	52	14	52	50	14	66	48	14
	70	51	14	53	50	14	56	51	14
	56	52	14	48	50	14	58	48	14
	72	52	14	55	46	14	53	48	14
	60	45	13	49	49	14	60	49	14
	62	48	14				51	48	14
	61	49	14				62	49	13
	58	47	13				49	49	14
	59	47	14				46	49	14
	58	52	14				56	51	14
	58	51	14				54	52	14
	47	44	12						
	43	47	14						
Mean (SD)	59.3 (8.27)	49.8 (2.63)	13.8 (0.52)	51.1 (1.98)	47.6 (2.07)	13.8 (0.58)	59.1 (9.48)	49.4 (1.46)	13.9 (0.24)
Range	43–74	44–52	12–14	48–55	44–50	12–14	46–80	47–52	13–14
Overall mean (SD)	57.2 (8.41)	49.1 (2.28)	13.9 (0.45)						
Overall range	43–80	44–52	12–14						

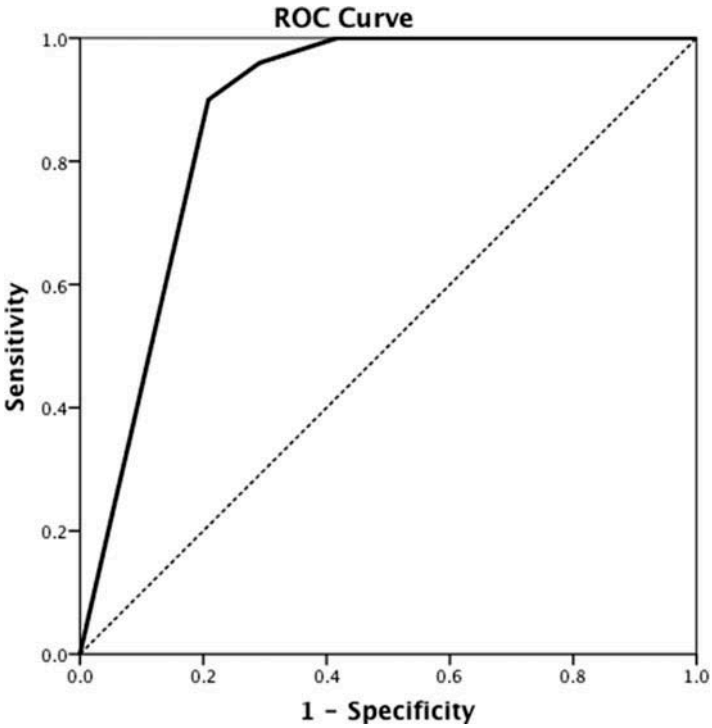

Figure 1. ROC analyses comparing controls to svPPA participants.
Note: Diagonal segments are produced by ties.

Across sites, controls' short-form scores were near perfect, mean = 13.9, standard deviation = 0.45, range = 12–14. Only seven total errors were made by controls, all on different items, meaning there was at least 98% accuracy for each item, mean = 99%, standard deviation = 1.0%. Full-form scores varied more widely, mean = 49.2, standard deviation = 2.27, range = 44–52. ROC analyses are shown in Figure 1.

A score of <12 on the short form accurately classified 100% of controls versus svPPA, specificity 100%; sensitivity 58%. A score of <13 had a specificity of 96% and sensitivity of 71%, area under the curve = 0.877, $p < .001$. For further analysis, we classified scores of 12–14 on the short-form PPT as normal. With this definition, none of our 50 controls scored outside the normal range on the short form, while 6/20 Argentinian, 7/12 Greek, and 5/18 American controls scored outside the published normal range of 49–52 on the full form. A chi-square test revealed that control performance was significantly more frequently classified as normal on the short form (≥12/14) versus the full form (≥49/52), χ^2 (3) = 32.84, $p < .001$.

Note that a score of <12 on the short-form PPT did not detect all of the individuals who were classified as having svPPA. Of the 24 individuals with svPPA, 10 scored above the cut-off for normal performance. Compared to the individuals with svPPA who were identified as having semantic impairments by the short-form PPT, these individuals were no different in terms of object picture naming, mean for high-scoring svPPA participants = 39.3%, standard deviation = 23.2%, mean for low-scoring svPPA participants = 37.9%, standard deviation = 28.9%, $t(22) = 0.13$, $p = .90$, or months since

Downloaded by [Aristotle University of Thessaloniki] at 01:11 20 December 2014

initial symptoms, mean for high-scoring svPPA participants = 33.3, standard deviation = 22.5, mean for low-scoring svPPA participants = 46.1, standard deviation = 34.5, $t(22) = -1.03$, $p = .32$. However, they did have better comprehension of objects as assessed by auditory picture–word matching tasks, mean for high-scoring svPPA participants = 81.3%, standard deviation = 19.4%, mean for low-scoring svPPA participants = 37.2%, standard deviation = 39.2%, $t(15.19) = 3.28$, $p = .005$. Compared to the individuals with lvPPA and nfvPPA, these individuals were more impaired on naming, mean for lvPPA participants = 66.6%, standard deviation = 30.9%, $t(31) = -2.49$, $p = .018$; mean for nfvPPA participants = 80.4%, standard deviation = 23.2%, $t(34) = -4.76$, $p < .001$, but were not more impaired on comprehension, mean for lvPPA participants = 88.1%, standard deviation = 11.8%, $t(25) = -1.13$, $p = .271$; mean for nfvPPA participants = 90.4%, standard deviation = 21.3%, $t(28) = -1.09$, $p = .285$, and had no differences in time since initial symptoms, mean for lvPPA participants = 47.9, standard deviation = 27.5, $t\ (31) = -1.48$, $p = .150$; mean for nfvPPA participants = 38.7, standard deviation = 26.4, $t\ (35) = -0.57$, $p = .570$. Of the 10 svPPA participants who scored above the cut-off in this study, five received repeat testing 11–24 months later. Of these, three continued to score above the cut-off (13/14–14/14). The remaining two participants demonstrated impaired performance on the short-form PPT with scores of 11/14 and 5/14, indicating that their semantic deficits had become more severe.

Imaging analysis

Table 2 shows performance for the 39 individuals with PPA who participated in imaging. Here, the two individuals with unclassifiable PPA were included as they increased the power of the analysis and because clinical variant was not a factor of the analysis. Performance on the short-form PPT was correlated with volume in the temporal lobes, including left inferior and superior temporal poles and anterior middle temporal gyrus as well as right fronto-orbital gyrus (Table 4).

Discussion

In this study, we developed a short form of the Pyramids and Palm Trees Test that efficiently and accurately assesses object semantics. We used three criteria in assessing the utility of the test: (1) healthy individuals across multiple cultures share the necessary semantic knowledge to complete the task; (2) poor performance on the test can be used to identify individuals with clinically significant semantic memory impairments, such as those with svPPA; and (3) performance on the assessment is associated with volume in the brain areas associated with semantic memory in previous research. We believe that an

Table 4. Imaging analysis results: regions where volume significantly correlated with performance on the short-form Pyramids and Palm Trees Test.

Region	Pearson's correlation r	Bonferroni corrected p
Left anterior middle temporal gyrus	0.550836	0.0212295
Right medial fronto-orbital gyrus	0.527293	0.0427402
Left inferior temporal pole	0.526545	0.0436647
Left superior temporal pole	0.523365	0.0477984

Downloaded by [Aristotle University of Thessaloniki] at 01:11 20 December 2014

assessment that fits all of these criteria is one that clinicians in a range of cultures can confidently use to rapidly detect significant semantic impairments.

In developing the assessment, we removed a number of items requiring culturally specific information. For example, one item in the full form asks subjects to associate WINDMILL with either TULIP or DAFFODIL. While both tulips and daffodils grow near windmills (e.g., in the Netherlands), the target associate is tulip. The correctness of the decision is not based solely on the meanings or defining features of the three objects but on the normative performance of people in the UK, where the assessment was created. When we removed many items that seemed to rely on cultural knowledge more than defining features, controls in three culturally diverse locations, Argentina, Greece, and the US, performed near ceiling. However, we do not claim to have selected items free of cultural bias or on which all speakers of the language agree. In all three countries, a few healthy controls made one or two nontarget responses on our selected items. Nevertheless, analyses confirm that neurologically intact participants are significantly more likely to achieve scores that are classified as normal on our short form (12–14/14) as compared to normal on the full form (using published norms), on which a greater range of performance was observed. Results indicate that our short form is a cross-culturally valid assessment of object semantics that can be used in a wide range of individuals with different life experiences. We invite further investigation of its application in additional culturally diverse locations.

Our definition of semantic memory for objects as knowledge of objects' defining features shared by speakers of the language is a conservative one. Some researchers include everything that one knows about an object in semantic memory (Caramazza, Hillis, Rapp, & Romani, 1990). Even if one would prefer a broader definition, items included in our assessment seem to tap semantic memory. While it is difficult to know what information participants used to complete the task, control participants appeared to have the requisite knowledge since they performed at such a high level. We can assume, therefore, that individuals with PPA premorbidly would have had the semantic knowledge necessary to correctly complete the task. Poor performance can be considered indicative of impairment in semantic memory.

The short-form PPT successfully identified significant impairments of semantic memory. In our assessment of primary progressive aphasia participants, those with the semantic variant performed significantly worse, as a group, than those with the logopenic or nonfluent agrammatic variants. At the single subject level, almost all the participants who performed below the level of the controls are characterised as semantic variant. The few others who performed poorly were in late stage PPA, when they had developed more global deficits as evidenced by available Mini Mental Status Examination (MMSE) scores (Folstein, Folstein, & McHugh, 1975). For example, the individuals initially diagnosed as lvPPA who scored 5/14 and 9/14 on the short-form PPT achieved scores of 3/30 and 9/30, respectively, on the MMSE.

As noted, the short form of the PPT did not identify all participants clinically diagnosed with svPPA. At the time of assessment, high-scoring svPPA participants as a group had relatively mild deficits in word comprehension though greater impairments in naming. These results show that the short-form PPT is sensitive to comprehension deficits, as it is designed to be. Individuals who have substantial semantic impairments that markedly affect comprehension are identified by the assessment, while those who do not have such impairments perform well. Later in the progression of the disorder, some svPPA participants who initially performed normally developed more severe semantic

Downloaded by [Aristotle University of Thessaloniki] at 01:11 20 December 2014

deficits detected by the short-form PPT, and others may later develop more severe semantic deficits that will be detectable with the short-form PPT.

The short-form PPT quickly identifies substantial impairments of semantic memory; however, a different version with a larger number of items with a greater range of performance would be better suited for characterising the degree or nature of semantic impairment. Because both the short and long forms of the PPT were normed at ceiling, this task is not well suited for making fine-grained parametric comparisons of performance to identify subtle deficits. Because item accuracy is very high across participants, each item has low discriminant power. Development of new assessments with greater sensitivity to subtle deficits and improved ability to describe semantic impairments is a promising direction for future research, which may benefit from attention to classical test design. The short-form PPT, however, is still a useful tool: Poor performance is clearly indicative of a deficit in semantic memory for objects. In combination with other instruments, such as tests of word comprehension, it can be used to aid diagnosis.

Future studies are needed to evaluate the sensitivity and specificity of the short form, relative to the complete test or other tests, for identifying individuals with svPPA. Such a determination requires a gold standard for identifying svPPA or semantic impairments. The gold standard for identifying svPPA due to frontotemporal lobar degeneration associated with TDP-43 (FTLD-TDP, the most common pathology associated with svPPA; Gorno-Tempini et al., 2011) would be pathologically confirmed FTLD-TDP or the presence of biomarkers (Grossman, 2014) or genetic mutations (Rohrer, 2014) associated with FTLD-TDP. Ongoing studies with our collaborators are identifying the sensitivity and specificity of the short-form PPT for identifying svPPA due to FTLD-TDP. However, some cases with the clinical syndrome of svPPA have Alzheimer's disease or other pathology (Grossman, 2014). To evaluate the validity of the short form for identifying all cases of clinical svPPA, one could use as a gold standard diagnosis by independent experts who use published criteria (e.g., Gorno-Tempini et al., 2011), based on videotapes of language and cognitive testing, history, and review of imaging. It is somewhat less clear what one would use as a gold standard for identifying all cases of semantic memory impairment (e.g., to compare the short form to the full form in individuals with PPA or dementia). This is an important clinical question, as individuals with a variety of clinical neurodegenerative syndromes can develop semantic memory impairment late in the course. The full-form PPT has been used as the only test of semantic memory in many studies of PPA and dementia. In this study, we have shown that healthy controls outside of the culture in which the test was normed sometimes score in the "impaired" range.

Another main finding of our study was that performance on the short-form PPT was correlated with volume in left anterior and inferior temporal cortex. Again, this is in accord with evidence implicating these areas in semantic memory. svPPA participants, who have impaired semantic memory, typically have focal atrophy in these areas (Galton et al., 2001; Gorno-Tempini et al., 2011; Mesulam et al., 2009; Mummery et al., 2000; Rosen et al., 2002). Most of the participants in our study who performed poorly on the short-form PPT were classified as svPPA. In contrast, those with lvPPA typically show atrophy in superior temporal and inferior parietal cortex, and those with nfvPPA have atrophy in posterior frontal cortex. Neither of these variants has impaired semantic memory, at least until late in the course of the disorder (Hillis et al., 2006, 2004, 2002; Thompson et al., 2012). Converging evidence implicates left anterior and inferior temporal cortex in semantic processing using a variety of methodologies, including neuroimaging of neurologically intact participants and neuropsychological studies of individuals with semantic deficits resulting from herpes simplex encephalitis, as well as

Downloaded by [Aristotle University of Thessaloniki] at 01:11 20 December 2014

acute and chronic stroke (Binder et al., 2009, 2011; Bright et al., 2004; Caramazza & Mahon, 2003; Devlin et al., 2000; Marinkovic et al., 2003; Newhart et al., 2007; Noppeney et al., 2007; Price et al., 2005; Rogers et al., 2006; Schwartz et al., 2009; Tyler & Moss, 2001; Visser et al., 2010). Our expected finding of a significant correlation between volume of the left anterior and inferior temporal cortex and performance on the short-form PPT offers further evidence that the assessment is tapping the underlying cognitive function of semantic memory.

It is somewhat surprising that error rate did not correlate with right anterior temporal lobe, as bilateral anterior temporal lobe damage is generally required to produce deficits in object semantics (Lambon Ralph, Cipolotti, Manes, & Patterson, 2010; Tsapkini, Frangakis, & Hillis, 2011). However, we may not have had adequate power to reveal the correlation with right anterior temporal lobe atrophy, as individuals with svPPA generally show greater left than right anterior temporal lobe atrophy (Gorno-Tempini et al., 2011; Mesulam et al., 2009).

There are several limitations of this study, some of which have been mentioned. The sample size was small, and the age range was relatively wide (as is generally the case for individuals with PPA). Age might influence performance, but we did not have an adequate number of participants of each age group to evaluate the influence of age. We also did not have a good measure of disease severity for the PPA participants. Nor did we compare the short form directly to the full form of the PPT in PPA participants. We therefore do not claim that it is "better" than, or even equal to, the full form of the test for evaluating PPA.

Overall, the short form of the Pyramids and Palm Trees Test can efficiently assess semantic memory for objects. With only 14 items, administration is carried out quickly: typically lesser than 5 min for unimpaired participants. Healthy controls across continents perform similarly well. We made an effort to include only items that can be answered on the basis of widely shared knowledge of defining features of objects. Clinically, it identifies individuals with impairments in semantic memory for objects, such as those with svPPA. Performance correlates with volume in neural areas previously implicated in semantic memory. This short form provides a useful clinical tool for identifying impairments in semantic memory.

Acknowledgements

We gratefully acknowledge the participation of the participants. We are grateful to David Howard and Karalyn Patterson for helpful comments on an earlier version of this manuscript. The content is solely the responsibility of the authors and does not necessarily represent the views the National Institutes of Health.

Disclosure statement

The authors have no potential conflicts of interest or relevant financial activities involving the work under consideration for publication (during the time involving the work, from initial conception and planning to present).

Funding

This research reported in this article was supported by the National Institutes of Health (National Institute of Deafness and Communication Disorders) [grant numbers R01 DC0111317 and R01 DC03681].

Downloaded by [Aristotle University of Thessaloniki] at 01:11 20 December 2014

References

Binder, J. R., Desai, R. H., Graves, W. W., & Conant, L. L. (2009). Where is the semantic system? A critical review and meta-analysis of 120 functional neuroimaging studies. *Cerebral Cortex*, *19*, 2767–2796. doi:10.1093/cercor/bhp055

Binder, J. R., Gross, W. L., Allendorfer, J. B., Bonilha, L., Chapin, J., Edwards, J. C., & Weaver, K. E. (2011). Mapping anterior temporal lobe language areas with fMRI: A multicenter normative study. *NeuroImage*, *54*, 1465–1475. doi:10.1016/j.neuroimage.2010.09.048

Bright, P., Moss, H., & Tyler, L. K. (2004). Unitary vs. multiple semantics: PET studies of word and picture processing. *Brain and Language*, *89*, 417–432. doi:10.1016/j.bandl.2004.01.010

Caramazza, A., Hillis, A. E., Rapp, B. C., & Romani, C. (1990). The multiple semantics hypothesis : Multiple confusions? *Cognitive Neuropsychology*, *7*, 161–189. doi:10.1080/02643299008253441

Caramazza, A., & Mahon, B. Z. (2003). The organization of conceptual knowledge: The evidence from category-specific semantic deficits. *Trends in Cognitive Sciences*, *7*, 354–361. doi:10.1016/S1364-6613(03)00159-1

Ceritoglu, C., Oishi, K., Li, X., Chou, M.-C., Younes, L., Albert, M., & Mori, S. (2009). Multi-contrast large deformation diffeomorphic metric mapping for diffusion tensor imaging. *NeuroImage*, *47*, 618–627. doi:10.1016/j.neuroimage.2009.04.057

Devlin, J. T., Russell, R. P., Davis, M. H., Price, C. J., Wilson, J., Moss, H. E., & Tyler, L. K. (2000). Susceptibility-induced loss of signal: Comparing PET and fMRI on a semantic task. *NeuroImage*, *11*, 589–600. doi:10.1006/nimg.2000.0595

Faria, A. V., Hoon, A., Stashinko, E., Li, X., Jiang, H., Mashayekh, A., & Mori, S. (2011). Quantitative analysis of brain pathology based on MRI and brain atlases—Applications for cerebral palsy. *NeuroImage*, *54*, 1854–1861. doi:10.1016/j.neuroimage.2010.09.061

Faria, A. V., Zhang, J., Oishi, K., Li, X., Jiang, H., Akhter, K., & Mori, S. (2010). Atlas-based analysis of neurodevelopment from infancy to adulthood using diffusion tensor imaging and applications for automated abnormality detection. *NeuroImage*, *52*, 415–428. doi:10.1016/j.neuroimage.2010.04.238

Folstein, M., Folstein, S., & McHugh, P. (1975). "Mini-Mental State": A practical method for grading the cognitive state of patients for the clinician. *Journal of Psychiatric Research*, *12*, 189–198. doi:10.1016/0022-3956(75)90026-6

Galton, C. J., Patterson, K., Graham, K., Lambon-Ralph, M., Williams, G., Antoun, N., … Hodges, J. R. (2001). Differing patterns of temporal atrophy in Alzheimer's disease and semantic dementia. *Neurology*, *57*, 216–225. doi:10.1212/WNL.57.2.216

Gorno-Tempini, M. L., Dronkers, N. F., Rankin, K. P., Ogar, J. M., Phengrasamy, L., Rosen, H. J., & Miller, B. L. (2004). Cognition and anatomy in three variants of primary progressive aphasia. *Annals of Neurology*, *55*, 335–346. doi:10.1002/ana.10825

Gorno-Tempini, M. L., Hillis, A. E., Weintraub, S., Kertesz, A., Mendez, M., Cappa, S. F., & Grossman, M. (2011). Classification of primary progressive aphasia and its variants. *Neurology*, *76*, 1006–1014. doi:10.1212/WNL.0b013e31821103e6

Grossman, M. (2014). Biomarkers in the primary progressive aphasias. *Aphasiology*, *28*, 922–940. doi:10.1080/02687038.2014.929631

Grossman, M., Mickanin, J., Onishi, K., Hughes, E., Esposito, M. D., Ding, X., & Reivich, M. (1996). Progressive nonfluent aphasia : Language, cognitive, and PET measures contrasted with probable Alzheimer's disease. *Journal of Cognitive Neuroscience*, *8*, 135–154. doi:10.1162/jocn.1996.8.2.135

Hillis, A. E., Heidler-Gary, J., Newhart, M., Chang, S., Ken, L., & Bak, T. H. (2006). Naming and comprehension in primary progressive aphasia: The influence of grammatical word class. *Aphasiology*, *20*, 246–256. doi:10.1080/02687030500473262

Hillis, A. E., Oh, S., & Ken, L. (2004). Deterioration of naming nouns versus verbs in primary progressive aphasia. *Annals of Neurology*, *55*, 268–275. doi:10.1002/ana.10812

Hillis, A. E., Tuffiash, E., & Caramazza, A. (2002). Modality-specific deterioration in naming verbs in nonfluent primary progressive aphasia. *Journal of Cognitive Neuroscience*, *14*, 1099–1108. doi:10.1162/089892902320474544

Hodges, J. R., Patterson, K., Oxbury, S., & Funnell, E. (1992). Semantic dementia: Progressive fluent aphasia with temporal lobe atrophy. *Brain*, *115*, 1783–1806. doi:10.1093/brain/115.6.1783

Howard, D., & Patterson, K. (1992). *Pyramids and Palm Trees Test*. London: Harcourt Assessment.

Downloaded by [Aristotle University of Thessaloniki] at 01:11 20 December 2014

Insausti, R., Juottonen, K., Soininen, H., Insausti, A. M., Partanen, K., Vainio, P., & Pitkänen, A. (1998). MR volumetric analysis of the human entorhinal, perirhinal, and temporopolar cortices. *American Journal of Neuroradiology*, *19*, 659–671. Retrieved from http://www.ajnr.org/content/19/4/659.abstract

Josephs, K. A., Duffy, J. R., Strand, E. A., Whitwell, J. L., Layton, K. F., Parisi, J. E., & Petersen, R. C. (2006). Clinicopathological and imaging correlates of progressive aphasia and apraxia of speech. *Brain*, *129*, 1385–1398. doi:10.1093/brain/awl078

Kondo, H., Saleem, K. S., & Price, J. L. (2003). Differential connections of the temporal pole with the orbital and medial prefrontal networks in macaque monkeys. *The Journal of Comparative Neurology*, *465*, 499–523. doi:10.1002/cne.10842

Kondo, H., Saleem, K. S., & Price, J. L. (2005). Differential connections of the perirhinal and parahippocampal cortex with the orbital and medial prefrontal networks in macaque monkeys. *The Journal of Comparative Neurology*, *493*, 479–509. doi:10.1002/cne.20796

Lambon Ralph, M. A., Cipolotti, L., Manes, F., & Patterson, K. (2010). Taking both sides: Do unilateral anterior temporal lobe lesions disrupt semantic memory? *Brain*, *133*, 3243–3255. doi:10.1093/brain/awq264

Marinkovic, K., Dhond, R. P., Dale, A. M., Glessner, M., Carr, V., & Halgren, E. (2003). Spatiotemporal dynamics of modality-specific and supramodal word processing. *Neuron*, *38*, 487–497. doi:10.1016/S0896-6273(03)00197-1

Mesulam, M., Wieneke, C., Rogalski, E., Cobia, D., Thompson, C. K., & Weintraub, S. (2009). Quantitative template for subtyping primary progressive aphasia. *Archives of Neurology*, *66*, 1545–1551. doi:10.1001/archneurol.2009.288

Mesulam, M. M. (1982). Slowly progressive aphasia without generalized dementia. *Annals of Neurology*, *11*, 592–598. doi:10.1002/ana.410110607

Mesulam, M.-M. (2007). Primary progressive aphasia: A 25-year retrospective. *Alzheimer Disease & Associated Disorders*, *21*, S8–S11. doi:10.1097/WAD.0b013e31815bf7e1

Mori, S., Oishi, K., Jiang, H., Jiang, L., Li, X., Akhter, K., & Mazziotta, J. (2008). Stereotaxic white matter atlas based on diffusion tensor imaging in an ICBM template. *NeuroImage*, *40*, 570–582. doi:10.1016/j.neuroimage.2007.12.035

Mummery, C. J., Patterson, K., Price, C. J., Ashburner, J., Frackowiak, R. S., & Hodges, J. R. (2000). A voxel-based morphometry study of semantic dementia: Relationship between temporal lobe atrophy and semantic memory. *Annals of Neurology*, *47*, 36–45. doi:10.1002/1531-8249(200001)47:1<36::AID-ANA8>3.0.CO;2-L

Nestor, P. J., Graham, N. L., Fryer, T. D., Williams, G. B., Patterson, K., & Hodges, J. R. (2003). Progressive non-fluent aphasia is associated with hypometabolism centred on the left anterior insula. *Brain*, *126*, 2406–2418. doi:10.1093/brain/awg240

Newhart, M., Ken, L., Kleinman, J. T., Heidler-Gary, J., & Hillis, A. E. (2007). Neural networks essential for naming and word comprehension. *Cognitive and Behavioral Neurology*, *20*, 25–30. doi:10.1097/WNN.0b013e31802dc4a7

Noppeney, U., Patterson, K., Tyler, L. K., Moss, H., Stamatakis, E. A., Bright, P., & Price, C. J. (2007). Temporal lobe lesions and semantic impairment: A comparison of herpes simplex virus encephalitis and semantic dementia. *Brain*, *130*, 1138–1147. doi:10.1093/brain/awl344

Oishi, K., Faria, A. V., Jiang, H., Li, X., Akhter, K., Zhang, J., & Mori, S. (2009). Atlas-based whole brain white matter analysis using large deformation diffeomorphic metric mapping: Application to normal elderly and Alzheimer's disease participants. *NeuroImage*, *46*, 486–499. doi:10.1016/j.neuroimage.2009.01.002

Oishi, K., Zilles, K., Amunts, K., Faria, A. V., Jiang, H., Li, X., & Mori, S. (2008). Human brain white matter atlas: Identification and assignment of common anatomical structures in superficial white matter. *NeuroImage*, *43*, 447–457. doi:10.1016/j.neuroimage.2008.07.009

Patterson, K., Nestor, P. J., & Rogers, T. T. (2007). Where do you know what you know? The representation of semantic knowledge in the human brain. *Nature Reviews Neuroscience*, *8*, 976–987. doi:10.1038/nrn2277

Price, C. J., Devlin, J. T., Moore, C. J., Morton, C., & Laird, A. R. (2005). Meta-analyses of object naming: Effect of baseline. *Human Brain Mapping*, *25*, 70–82. doi:10.1002/hbm.20132

Rogalsky, C., Love, T., Driscoll, D., Anderson, S. W., & Hickok, G. (2011). Are mirror neurons the basis of speech perception? Evidence from five cases with damage to the purported human mirror system. *Neurocase*, *17*, 178–187. doi:10.1080/13554794.2010.509318

Downloaded by [Aristotle University of Thessaloniki] at 01:11 20 December 2014

Rogers, T. T., Hocking, J., Noppeney, U., Mechelli, A., Gorno-Tempini, M. L., Patterson, K., & Price, C. J. (2006). Anterior temporal cortex and semantic memory: Reconciling findings from neuropsychology and functional imaging. *Cognitive, Affective & Behavioral Neuroscience*, *6*, 201–213. doi:10.3758/CABN.6.3.201

Rohrer, J. D. (2014). The genetics of primary progressive aphasia. *Aphasiology*, *28*, 941–947. doi:10.1080/02687038.2014.911242

Rosen, H. J., Kramer, J. H., Gorno-Tempini, M. L., Schuff, N., Weiner, M., & Miller, B. L. (2002). Patterns of cerebral atrophy in primary progressive aphasia. *The American Journal of Geriatric Psychiatry*, *10*, 89–97. doi:10.1097/00019442-200201000-00011

Schwartz, M. F., Kimberg, D. Y., Walker, G. M., Faseyitan, O., Brecher, A., Dell, G. S., & Coslett, H. B. (2009). Anterior temporal involvement in semantic word retrieval: Voxel-based lesion-symptom mapping evidence from aphasia. *Brain*, *132*, 3411–3427. doi:10.1093/brain/awp284

Stefanacci, L., Suzuki, W. A., & Amaral, D. G. (1996). Organization of connections between the amygdaloid complex and the perirhinal and parahippocampal cortices in macaque monkeys. *The Journal of Comparative Neurology*, *375*, 552–582. doi:10.1002/(SICI)1096-9861(19961125)375:4<552::AID-CNE2>3.0.CO;2-0

Thompson, C. K., Lukic, S., King, M. C., Mesulam, M. M., & Weintraub, S. (2012). Verb and noun deficits in stroke- induced and primary progressive aphasia : The Northwestern Naming Battery. *Aphasiology*, *26*, 632–655. doi:10.1080/02687038.2012.676852

Tsapkini, K., Frangakis, C. E., & Hillis, A. E. (2011). The function of the left anterior temporal pole: Evidence from acute stroke and infarct volume. *Brain*, *134*, 3094–3105. doi:10.1093/brain/awr050

Tulving, E. (1972). Episodic and semantic memory. In E. Tulving & W. Donaldson (Eds.), *Organization of memory* (pp. 381–402). New York, NY: Academic Press.

Tyler, L. K., & Moss, H. E. (2001). Towards a distributed account of conceptual knowledge. *Trends in Cognitive Sciences*, *5*, 244–252. doi:10.1016/S1364-6613(00)01651-X

Visser, M., Jefferies, E., & Lambon Ralph, M. A. (2010). Semantic processing in the anterior temporal lobes: A meta-analysis of the functional neuroimaging literature. *Journal of Cognitive Neuroscience*, *22*, 1083–1094. doi:10.1162/jocn.2009.21309

Warrington, E. K. (1975). The selective impairment of semantic memory. *The Quarterly Journal of Experimental Psychology*, *27*, 635–657. doi:10.1080/14640747508400525

Downloaded by [Aristotle University of Thessaloniki] at 01:11 20 December 2014